



INTERNATIONAL JOURNAL OF CREATIVE RESEARCH THOUGHTS (IJCRT)

An International Open Access, Peer-reviewed, Refereed Journal

NOVEL GAZETTES OF MUCORMYCOSIS

Sakshi Deepak haral.

Shivajirao pawar college of pharmacy pachegaon, ahmednagar 413725.

Abstract

- Mucormycosis is a fungal infection that occurs in immunocompromised (weak immune system) patient.
- Mucormycosis is also called as ZYGOMYCOSIS, Black fungi.
- Throughout the history of mucormycosis, from the first case in humans reported in 1885 by Paltauf, through publication by Gregory et Al of the first observation of rhino-orbital cerebral mucormycosis in 1943, to the report by Harris in 1955 of the first known survivor, little has changed in the diagnosis and out come.
- Recent data support the concept that high dose liposomal amphotericin is the preferred monotherapy for mucormycosis.
- These options include combination therapy using lipid based amphotericin with an echinocandin or with an azole (largely isavuconazole or posaconazole) or with all three.
- The underlying principal of therapy for this disease remain rapid diagnosis, reversal of underlying predisposition and urgent surgical debridement (I.e. procedure for treating a wound in the skin involve cleaning wound and removing all hyperkeratotic, infected and nonviable tissue, foreign debris and residual material from dressing.
- Diabetes mellitus and COVID 19 is an independent risk factor for mucormycosis.

In this article we will examine the clinical and

- In this article we will examine the clinical and research issue regarding this rapidly changing field.
- It is clear that iron metabolism plays a central role in regulating mucormycosis infection and that deferoxamine predisposes patients to mucormycosis by inappropriately supplying the fungus with iron.

Introduction

- Mucormycosis is a fungal infection caused by certain types of mold. These mould are known as mucormycetes.

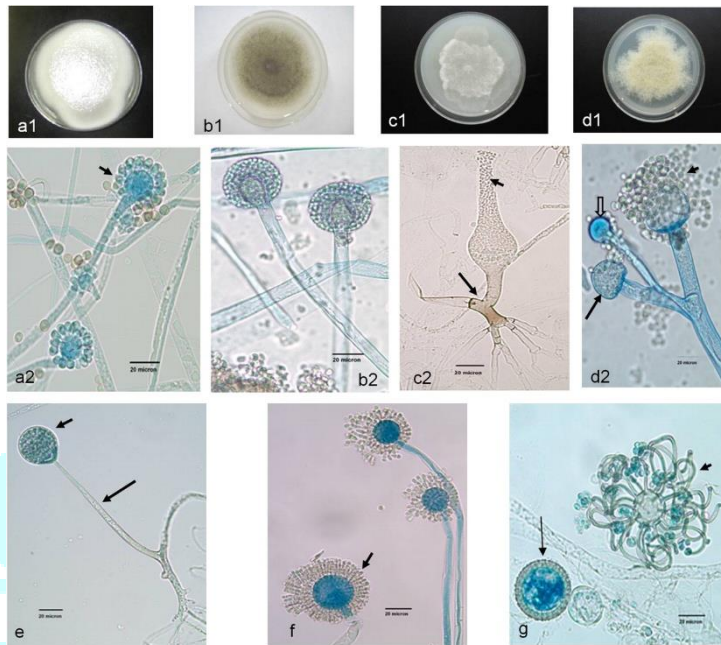


Fig:- mucormycetes.

- It's mostly occurring in hematology, solid organ transplants, diabetes and COVID 19 patients.
- These infection are difficult to manage for several reasons. Firstly, diagnosis is difficult because of clinico-radiological similarities with invasive aspergillosis and historical lack of diagnostic tools.
- Secondly, treatment is an emergency and combines surgery, which is frequently required owing to the angioinvasive and necrotic character of infection, and antifungal treatment.
- Humans mucormycosis are caused by a wide range of pathogenic species. Mucormycosis location is linked to the mucorales species, *Rhizopus arrhizus*.
- Mucorales is a complex fungal group, including eleven different genera that can infect humans.
- Mucorales fungi are distributed worldwide and found in decaying organic substrates.
- The mucorales comes under the fungi zygomycetes.
- It takes a asexual reproduction in mucorales. It takes place by means of non-motile spore (sporangiospores).
- The most common way these infection get into your body is by inhaling dust and other particles from dirty, dark and moist environment. Where this kind of fungi lives which, in case of India, is likely due to unhygienic oxygen and overuse of steroids on COVID 19 patients.
- The black fungus (mucormycosis) can be identified by the following ways.
 - i. Experience nasal blocked
 - ii. Facial pain
 - iii. Black discoloration
 - iv. Tooth pain
 - v. Pulmonary issues

- vi. Vision troubles
- vii. High fever
- viii. Blood clots
- ix. Skin lesions.

Pathogenesis.

A. Host defense.

- Both mononuclear and polymorphonuclear phagocytes of normal host like mucorales by the generation of oxidative metabolites and the cationic peptides defensins.

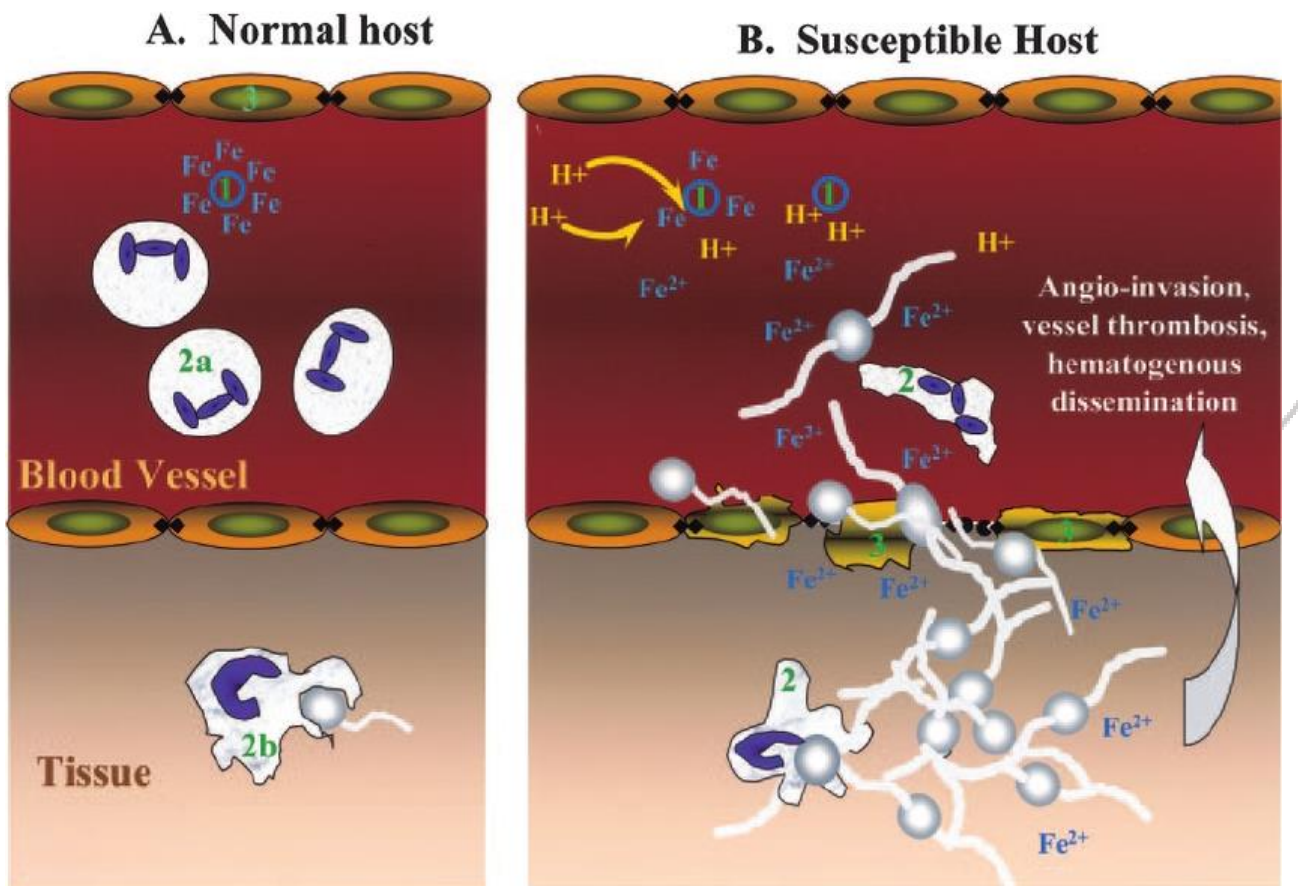


Fig1 pathogenetic mechanism of and host defense.

- Clinical evidence demonstrate that these phagocytes are the major host defense mechanism against mucormycosis. eg. neutropenic patient are at increase risk of developing mucormycosis. Further more , patient with dysfunctional phagocytes are also at higher risk for developing mucormycosis.
- Hyperglycemia and acidosis are known to impaired the ability of phagocytes to move towards and kill the organisms by both oxidative and nonoxidative mechanism. Additionally, corticosteroid treatment affect the ability of mouse bronchoalveolar macrophages to prevent germination of the spores in vitro or after in vivo infection induced by intranasal inoculation.

B. Role of iron in pathogenesis.

A recently identified important clinical feature is the increased susceptibility to mucormycosis of patients with elevated available serum iron. It has been known for two decades that patients treated with the iron chelator deferoxamine have a markedly increased incidence of invasive mucormycosis. However, it is now clear that iron chelation is not the mechanism by which deferoxamine enables mucormycosis infections. While deferoxamine is an iron chelator from the perspective of the human host, *Rhizopus* spp. actually utilize deferoxamine as a siderophore to supply previously unavailable iron to the fungus. *Rhizopus* spp. can accumulate 8- and 40-fold-greater amounts of iron supplied by deferoxamine than can *Aspergillus fumigatus* and *Candida albicans*, respectively, and this increased iron uptake by *Rhizopus* spp. is linearly correlated with its growth in serum. Additionally, data from animal models emphasize the exceptional requirement of iron for *Rhizopus* pathogenicity since administration of deferoxamine or free iron worsens survival of animals infected with *Rhizopus* spp. but not *Candida albicans*. Finally, animal models have demonstrated that other iron chelators, which are not used as siderophores by the fungus, do not similarly exacerbate mucormycosis infection.

Patients with diabetic ketoacidosis are at high risk of developing rhinocerebral mucormycosis. Multiple lines of evidence support the conclusion that patients in systemic acidosis have elevated levels of available serum iron, likely due to release of iron from binding proteins in the presence of acidosis. For example, sera collected from patients with diabetic ketoacidosis supported growth of *Rhizopus oryzae* in the presence of acidic pH (7.3 to 6.88) but not in the presence of alkaline pH (7.78 to 8.38). Acidic sera that supported the growth of *R. oryzae* were found to contain increased available serum iron (69 µg/dl versus 13 µg/dl for sera which did not support the growth of *R. oryzae*). Finally, simulated acidotic conditions decreased the iron-binding capacity of sera collected from normal volunteers, suggesting that acidosis temporarily disrupts the capacity of transferrin to bind iron. Therefore, the increased susceptibility to mucormycosis of patients with diabetic ketoacidosis is likely due at least in part to an elevation in available serum iron during diabetic ketoacidosis.

Physical examination.

Clinical presentation is classified according to the organ involvement as follows.

- a. Rhino-cerebral mucormycosis.
- b. Pulmonary mucormycosis
- c. Cutaneous mucormycosis
- d. Gastrointestinal mucormycosis
- e. Miscellaneous forms.

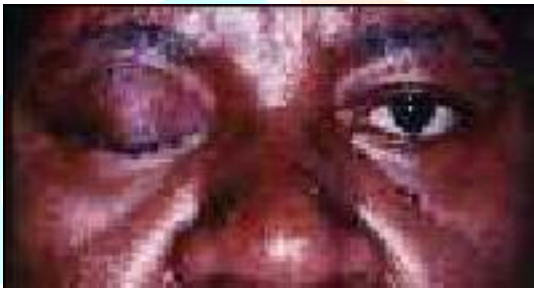a. Rhino-cerebral mucormycosis

Rhinocerebral mucormycosis is a rare opportunistic infection of the sinuses, nasal passages, oral cavity, and brain caused by saprophytic fungi. The infection can rapidly result in death. Rhinocerebral [mucormycosis](#) commonly affects individuals with diabetes and those in immunocompromised states. Rare variants of [mucormycosis](#) include lingual, pulmonary, cutaneous, gastrointestinal (GI), and disseminated forms. 50% of cases occurs of DM.

An underlying risk factor is recognized in more than 96% of mucormycosis cases. Risk factors for rhinocerebral mucormycosis include the following:

- [Diabetes mellitus](#)
 - Iron overload
 - Burns
 - Human immunodeficiency virus (HIV) and acquired immunodeficiency syndrome (AIDS)
 - Blood dyscrasias
 - Transplantation
 - Immunosuppression (ie, prednisone therapy)
 - Chemotherapy
 - Intravenous drug use - Embolic to brain
 - Disease states treated with high-dose steroids
- Diabetes mellitus

This condition is a risk factor, particularly in association with poor glycemic control and acidosis, as it relates to cellular immune dysfunction. Patients with diabetes are predisposed to mucormycosis because of the decreased ability of their neutrophils to phagocytize and adhere to endothelial walls. Furthermore, the acidosis and hyperglycemia provide an excellent environment for the fungus to grow.



This diabetic patient with mucormycosis presented with complete ophthalmoplegia and proptosis. Note the complete ptosis and periorbital edema on the right side.

Iron overload

Iron overload states, as observed with [hemosiderosis](#) and deferoxamine treatment in patients receiving dialysis, may be risk factors. Iron enhances fungal growth and increases susceptibility. Researchers have reported infection in patients with liver and renal failure.

Burns

In individuals with burns, mucormycosis generally involves only the skin and rarely results in rhinocerebral infection.

Blood dyscrasias

These include lymphoma, prolonged neutropenia, and leukemia. Researchers estimate that the incidence of mucormycosis in persons with hematologic malignancy is approximately 1%.

Transplantation

This includes solid organ (eg, liver, kidney) and bone marrow transplantation. Maertens et al found that the incidence of mucormycosis in recipients of allogeneic bone marrow transplants was 1.9%. However, most cases do not involve the central nervous system (CNS). [Graft versus host disease](#) (GVHD) and donor leukocyte infusions are also risk factors.

Disease states treated with high-dose steroids

One case report described mucormycosis in a patient with an adrenal corticotrophic hormone (ACTH)-producing pulmonary tumor associated with Cushing syndrome

B pulmonary mucormycosis

Pulmonary mucormycosis (PM) is an uncommon fungal infection most often seen in immunocompromised patients. The fungus grows on decaying food, soil, and animal excrement. Patients usually become infected by inhalation of spores.

Some of the common symptoms of the pulmonary mucormycosis are as follows

Fever

Cough

Chest pain

Shortness of breath

Hemoptysis

C. Cutaneous mucormycosis

Cutaneous (skin) mucormycosis can look like blisters or ulcers and the infected area may turn black other symptoms include pain, warmth, excessive redness, or swelling around a wound.

The agents of mucormycosis are ubiquitous in nature and are transmitted to the skin by direct inoculation, as a result of various types of trauma. These include needle sticks, stings and bites by animals, motor vehicle accidents, natural disasters, and burn injuries.

D. Gastrointestinal mucormycosis.

Primary gastric mucormycosis is a rare but potentially lethal fungal infection due to the invasion of Mucorales into the gastric mucosa. It may result in high mortality due to increased risk of complications in immunocompromised patients. Common predisposing risk factors to develop gastric mucormycosis are prolonged uncontrolled diabetes mellitus with or without diabetic ketoacidosis (DKA), solid organ or stem cell transplantation, underlying hematologic malignancy, and major trauma. Abdominal pain, hematemesis, and melena are common presenting symptoms. The diagnosis of gastric mucormycosis can be overlooked due to the rarity of the disease. Among gastrointestinal mucormycosis, the stomach is the most commonly affected organ (67%), followed by the colon (21%), small intestine (4%), and esophagus (2%).

E. Miscellaneous form.

A fifth type has been described as **mucormycosis** of the kidney, or miscellaneous, that is mucormycosis at other sites, although less commonly affected.

Treatment.

A. Antifungal combination.

- **Liposomal and lipid complex amphotericin B.**

Amphotericin B has proven efficacy in the treatment of mucormycosis . The liposomal formulation (ambisome) is the drug of choice based on the efficacy and safety data. Amphotericin B deoxycholate can also be used to treat mucormycosis, particularly when other formulation prove too costly.

The typical dose is 1-1.5mg/kg/d . The total dose given over the course of the therapy is usually 2.5-3 g . High doses of this drug are required, and nephrotoxicity may result. This is of particular concern because many patients who develop black fungi have pre-existing renal disease.(e.g, diabetes, transplant recipients.) Monitoring the renal function of patients taking amphotericin B is critical . doubling of serum creatinine over the baseline levels I'd an indication for changing to liposomal amphotericin B. In additional monitoring and repletion of serum electrolytes (eg.potassium, phosphorus,magnesium) should be performed when administering any formulation of amphotericin B.

- **Isavuconazole.**

Isavuconazole (cresemba) is a novel triazole antifungal agent that was approved for the treatment of MUCORMYCOSIS in March 2015. The prodrug isavuconazonium sulfate is rapidly metabolized by serum butylcholinesterase to the active form ,isavuconazole(ISZ). The efficacy of isavuconazole in the treatment of invasive mucormycosis has not been evaluate in the randomized controlled trials because of the rarity of this disease. The approval of this medication was based on the non comparative ,single arm ,open label ,matched ,case control trials.(VITAL).of 149 patients enrolled,37 has proven (86%) or probable (14%) mucormycosis twenty-one patients received primary treatment with ISZ, where as 11 patient receive isavuconazole salvage therapy;5 were intolerant to other antifungal.complex ,21% deoxycholate we're matched from the fungi scope registry.

- **Other agents and combination therapy.**

Most mucorales species show moderate invitro resistance to the echinocandins ; these agents cannot be used in the treatment of mucormycosis. Animal and limited clinical data have suggested that combination therapy with amphotericin and an echinocandins may improve survival. However, a recent retrospective cohort study of combination liposomal amphotericin B with posaconazole ,L-AMB with echinocandins and posaconazole with echinocandins showed no difference in the mortality between monotherapy and combination treatment groups.

Further clinical trial are needed before antifungal combination therapy can be definitively recommended .currently there is a clinical trial assessing the combination of inhaled amphotericin+ IV liposomal amphotericin B vs IV amphotericin alone, and other novel therapies are being evaluated out based on medical patent review and invitro data.

B. Surgical debridement.

Aggressive early surgical debridement of the infected craniofacial tissues is the cornerstone of successful treatment of ROCZ mucormycosis. This includes resection of involved tissues of the face, including skin and muscle, any skin of the nose that is involved, maxillary and ethmoid sinuses, necrotic tissue of the temporal area and infratemporal fossa, and orbital exenteration. Orbital exenteration may be life-saving in the presence of active fungal invasion of the orbit and should be considered for an actively infected orbit with a blind, immobile eye. It has been considered helpful even after intracranial spread has occurred. Whether or not to perform orbital exenteration is the most difficult decision in the surgical management of orbital mucormycosis because the procedure may represent a life-saving measure achieved at the cost of permanent mutilation .

Surgical debridement usually proceeds quickly because of an almost bloodless field. An aggressive surgical approach appears to enhance survival. The keys to successful therapy include suspicion of the diagnosis with early recognition of the signs and symptoms, correction of underlying medical disorders such as ketoacidosis, and aggressive medical and surgical intervention.

Conclusion.

There are many unresolved issue concerning the epidemiology, diagnosis and treatment of mucormycosis. Although important advance have been made ,there is still a need for better diagnostic tests in order to accurately identify patients with mucormycosis and initiate appropriate treatment as early as possible. Based on the existing data , critical gaps in the knowledge remain regarding management of these infection, including combination therapy , evaluation of response and surgical debridement.

References

1. A systematic review of cases reported worldwide and in India. (Awadhesh Kumar Singh, Ritu Singh, and Anoopmisra)
2. Recent advance in the understanding and management of mucormycosis.(Benoit pilmis,Alexandre alanio and Fanny lanternier).
3. Mucormycosis (ZYGOMYCOSIS) treatment and management.(Anish Sandhu).
4. Novel perspective on mucormycosis.(Brad spellberg,John Edward,Jr and Ashraf Ibrahim.)
5. Gastric mucormycosis: An infection of fungal invasion into the gastric mucosa in Immunocompromised patients.(Haider A.Naqvi, Muhammad Nadeem Yousaf,Fizah s. Chaudhary,and Lawrence Mills.)