



A Constitutional Homoeopathic Approach In The Treatment Of Acne Vulgaris: An Evidence-Based Case Study

Dr DIVYA V ^[1]

Dr MURUGAN M ^[2]

P.G Scholar, Department of Organon of Medicine and Homoeopathic Philosophy, Sarada Krishna Homoeopathic Medical College and Hospital (Affiliated to The Tamil Nadu Dr. M.G.R. Medical University) Kulasekharam, Kanyakumari, Tamil Nadu - 629161

Professor & Head, Department of Organon of Medicine and Homoeopathic Philosophy, Sarada Krishna Homoeopathic Medical College and Hospital (Affiliated to The Tamil Nadu Dr. M.G.R. Medical University) Kulasekharam, Kanyakumari, Tamil Nadu - 629161

ABSTRACT:

Acne vulgaris is a common inflammatory skin disorder involving comedones, papules, pustules, nodules, and scars, affecting over 80% of teenagers and persisting into adulthood in some cases. While not life-threatening, it often causes scarring and significant psychological distress. This case study highlights the effectiveness of Constitutional Homoeopathic remedy in treating Acne vulgaris and enhancing the Quality of Life of the patient. A 25-year-old female with a 10-year history of facial acne presented with blackish nodular eruptions. Detailed case-taking identified characteristic physical and mental symptoms. The totality of symptoms was made and repertorisation was done with Zomoeo pro software. Global Acne Grading System score and Dermatology Life Quality Index score were recorded at baseline and monthly follow-ups, with series of photographic documentation. The MONARCH criteria assessed the causal relationship between constitutional remedy and the clinical improvement. Based on repertorial result and referring various Materia medica, *Natrum muriaticum* 1M was prescribed followed by *sacrum lactum* for one month. The same prescription repeated for next three months. The Global Acne Grading System score improved from 16 to 0 and the Dermatology Life Quality Index score from 13 to 0 with complete resolution of eruptions over the cheeks and no recurrence seen during treatment. The MONARCH score increased from 4 to 11. The photographic evidence was well-documented. This case demonstrates that carefully selected constitutional remedy can effectively restore both the physical manifestations and the psychological burden associated with chronic dermatological conditions. While a single case cannot establish definitive proof of efficacy, the favourable clinical outcome substantiated by sequential photographic documentation provides supporting evidence to Constitutional homoeopathic treatment as a valuable therapeutic approach for acne vulgaris.

Keywords: *Acne Vulgaris, Constitutional Remedy, Natrum Muriaticum, Quality of Life*

INTRODUCTION:

Acne vulgaris is an inflammatory disease of pilosebaceous gland characterised by comedones, pustules, papules, nodules, scars. Over 80% of teenagers affected by Acne vulgaris. Beyond the age of 25 years in 3% of men and 12% of women, it persists. Lesions are most commonly presented on face, but the neck, chest, upper back, and shoulders may also be affected. Acne can cause scarring and considerable psychological distress.^[1]

The Global Burden of Disease Study 2010 found that acne vulgaris is the eight most common skin disease, with an estimated global prevalence for all ages of 9.38%^[2]. In different countries and among different age groups, the prevalence of acne varies, with estimates ranging from 35% to close to 100% of adolescents having acne at some point.^[3] Acne persists into the 20s and 30s in around 64% and 43% of individuals, respectively.^[4] Acne is not life-threatening, it can have a significant psychosocial impact, contributing to anxiety, low self-esteem, social withdrawal, and impaired quality of life.

This case report demonstrates the effectiveness of the Constitutional Homoeopathic remedy in treating Acne Vulgaris and improving the patient's overall Quality of life.

CASE REPORT:

A 25-year female patient presented with the complaint of blackish nodular eruption on both the cheeks for 10 years and worse since 3months. Occasionally itching present. She had dry skin with profuse perspiration. Her complaint gets aggravated on exposure to sun and ameliorated by washing face in cold water.

HISTORY OF PRESENTING COMPLAINT:

Before 10 years, her complaint started as a pustular eruption on cheeks. She used to take allopathic medication and gets temporary relief. After some years, she had nodular eruption on both the cheeks. Since 3months her complaint gets worse. The severity of the nodular eruption increased. Occasionally she had itching over the nodular eruption. She had dry skin with profuse perspiration. Her complaint gets aggravated on exposure to sun and ameliorated by washing face in cold water.

PHYSICAL GENERAL:

Appetite: 3 Meals/day (normal)	Thermals: Hot patient
Thirst: Excessive	Fanning: Desire
Urine: 3-4 times/day	Covering:
Stool: Once a day regular	According to climate
Sleep: Normal (8hours/day refreshed sleep)	Drinking: Ordinary water
Perspiration: Profuse	Bathing: Ordinary water
Dreams: Running, teeth falling out	
Desire: Sweets	

Table 1: Physical generals

MENTAL GENERALS:

1. Introvert
2. Dependent
3. Anxious about future
4. Fear of strangers
5. Fear of crowds
6. Brooding about past events

MENSTRUAL HISTORY:

Cycle: 3/28 days

Flow: Normal

Colour: Bright red colour

Consistency: Normal with no clots

PHYSICAL EXAMINATION:**Skin:**

- Of Face – Nodular eruption on both cheeks. Blackish spots seen. No redness. No discharges seen.
- Of Neck – no pigmentation seen.

GLOBAL ACNE GRADING SYSTEM:

<u>Region</u>	<u>Factor</u>	<u>Lesion score</u>	<u>Regional Score</u>
Forehead	2	0	0
Right Cheek	2	4	8
Left Cheek	2	4	8
Nose	1	0	0
Chin	1	0	0
Chest	3	0	0
Upper Back	3	0	0

Table 2: Global Acne Grading System

Total GAGS Score = 16

DERMATOLOGY LIFE QUALITY INDEX QUESTIONNAIRE:**REPEDITORIZATION:**

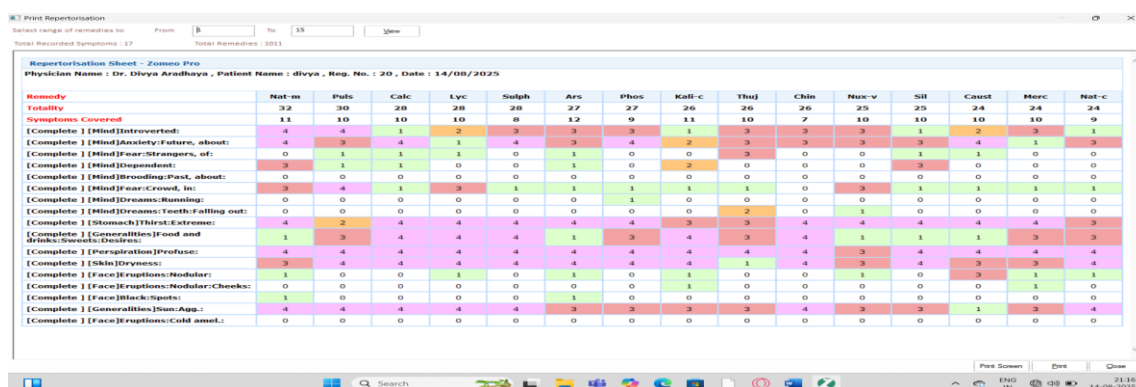
DOMAIN	SCORE
Symptoms & Feelings	2
Daily Activities	2
Leisure	3
Impact in Work/School life	2
Personal Relationships	3
Treatment effect	1

Table 3: Dermatology Life Quality Index Questionnaire

DLQI Score: 13 → Moderate impact on quality of life

TOTALITY OF SYMPTOMS:

1. Introvert
2. Dependent
3. Anxious about future
4. Fear of strangers
5. Fear of crowds
6. Brooding about past events
7. Dreams: running, teeth falling out
8. Thirst: Excessive
9. Desire: sweets
10. Dry skin with profuse perspiration.
11. Blackish nodular eruption on both the cheeks
12. < On exposure to Sun
13. > Washing face in cold water

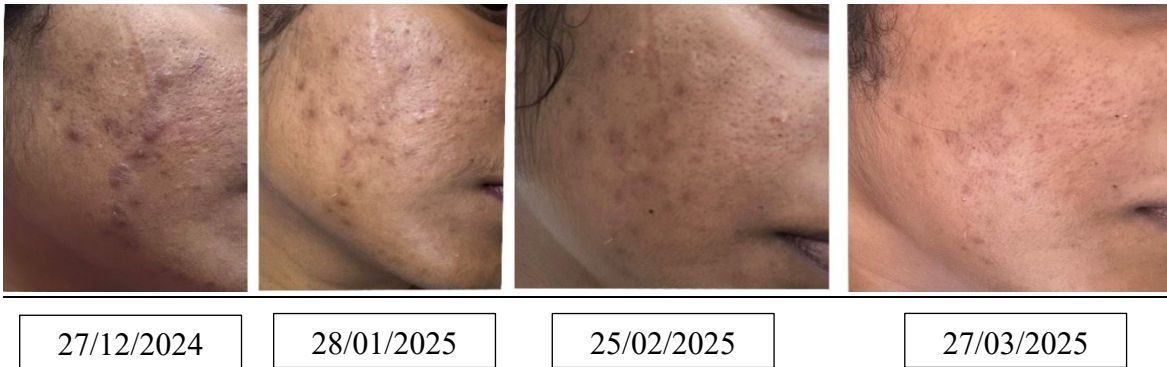
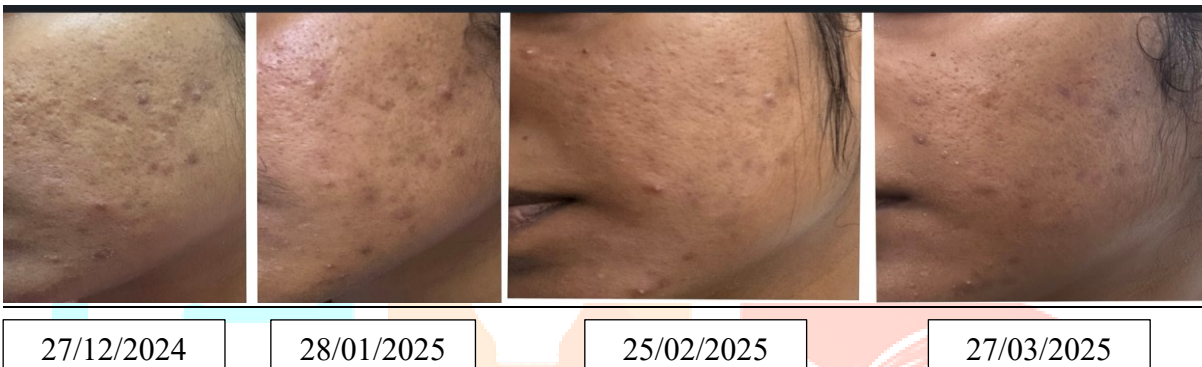
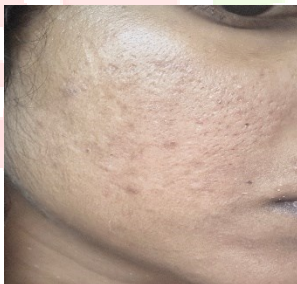**Figure 1 : Repertorial Chart**

RESULT:

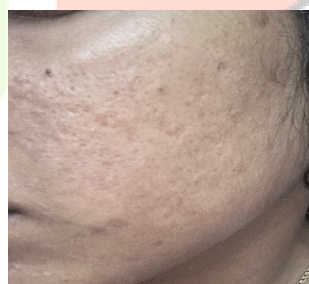The patient was clinically diagnosed with Acne Vulgaris based on characteristic signs and symptoms. Global acne grading system was used to access the change in the lesion severity and Dermatology Life Quality Index Questionnaire was used to assess the improvement in the quality of life of the patient. Based on repertorial result and by referring the various Materia medica books, Natrum muriaticum 1M, one 30 sized medicated globule with one grain of sugar of milk was prescribed and asked to take orally at night before bed, followed by Sacrum Lactum for one month. The same prescription was repeated for next three month. On the 1st visit, GAGS score was 16 and after 4months of treatment GAGS score was reduced to 2. The eruption on the cheeks completely disappeared and no recurrence was found during the course of treatment. The quality of life of the patient improved, based on the DLQI score which reduced from 13 to 2.

Table 4: Follow Up

DATE	SYMPTOMS	PRESCRIPTION
28/01/2025	Blackish nodular eruption still persists on both cheeks Blackish pigmentation seen No other new complaint All generals normal GAGS: 16 DLQI: 13	R _x 1. NATRUM MURIATICUM 1M / One dry DOSE (one 30 sized medicated globule with one grain of sugar of milk) (HS) 2. SAC LAC X 4 Weeks
25/02/2025	Blackish nodular eruption reduced on both cheeks Blackish pigmentation reduced No other new complaint All generals normal GAGS: 12 DLQI: 8	R _x 1. NATRUM MURIATICUM 1M / One dry DOSE (one 30 sized medicated globule with one grain of sugar of milk) (HS) 2. SAC LAC X 4 Weeks
27/03/2025	Mild blackish pigmentation seen on both the cheeks. No other new complaint All generals normal GAGS: 4 DLQI: 2	R _x 1. NATRUM MURIATICUM 1M / One dry DOSE (one 30 sized medicated globule with one grain of sugar of milk) (HS) 2. SAC LAC X 4 Weeks
25/04/2025	No eruptions seen No pigmentation seen No other new complaint All generals normal GAGS: 0 DLQI: 0	R _x 1. SAC LAC X 4 Weeks

Right cheek (Before):Left cheek (Before):Right cheek (After):

25/04/2025

Left cheek (After):

25/04/2025

DISCUSSION:Concepts of Constitution in Homoeopathy according to Stalwarts:

Stuart close defines constitution as “that aggregate of hereditary characters, influenced more or less by the environment which determines the individual’s reaction, successful or unsuccessful, to the stress of environment”.[5]

Dr. Kent says “The perceptible ailment that follows a disorder in the man’s vital power is called physical constitution”.[6]

According to Philip M. Bailey, Constitutional prescribing means selecting the remedy which covers the totality of the patient’s symptoms (both physical and mental) at a given time.[7]

Dr. M.L Dhawale says that everyone has a unique characteristic that gives them their personality, which is partly affected by genes and environmental factors throughout their lives.^[8] Dr. Sushma S. Manhas et. al (April 2023), made a narrative review on Constitutional treatment in homoeopathy. The aim of this review article was to summarize and review the available literature on the homoeopathic constitutional treatments. They had collected various research works and studies from literature books and database such as PubMed, Google Scholar and Cochrane Library and concludes that there is clear evidence that homeopathic constitutional treatment is effective and useful in treating a number of clinical conditions without harming the sick individuals.^[9] In this case, the constitutional remedy *Natrum muriaticum* was selected based on the patient's characteristic mental generals, physical generals, and specific modalities. The potency **1M** was chosen based on the following:

- The presence of predominant mental generals strongly indicated the need for a higher potency.

- The remedy closely matched the totality of symptoms presented by the patient.
- Remedies that are relatively inert in their crude state often yield better results in higher potencies.^[8]

A remedy should not be administered before or during its natural aggravation period.^[8] As *Natrum muriaticum* tends to aggravate in the morning, it was prescribed to be taken at bed-time. Furthermore, higher potencies should not be repeated frequently.^[10] Therefore, the prescription was limited to one dose only, followed by sac lac. According to aphorism 193 of Organon of Medicine, "local affection depends solely on a disease of the rest of the body, and should be regarded as an inseparable part of the whole, as one of the most considerable and striking symptoms of the whole."^[11] Hence this constitutional prescription addressed not only the local cutaneous lesions but also the underlying susceptibility and psychosomatic factors contributing to the chronicity of the condition. The photographic evidence documented the progressive reduction in pigmentation, resolution of nodular eruptions and restoration of clear skin.

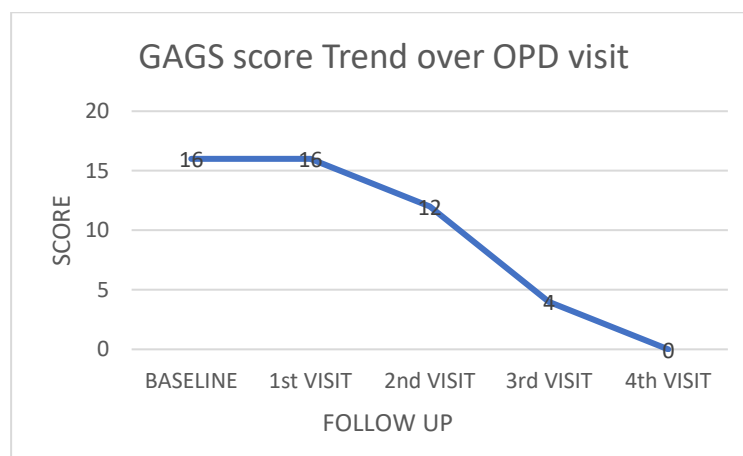


FIGURE 2: Graphical Representation of Improvement in GAGS Score

Within four months, the GAGS score declined from 16 to 0, signifying complete clearance of acne lesions

DOMAIN	Baseline	1 st visit	2 nd visit	3 rd visit	4 th visit
Symptoms & Feelings	2	2	1	0	0
Daily Activities	2	2	1	0	0
Leisure	3	3	2	1	0
Impact in Work/School life	2	2	1	0	0
Personal Relationships	3	3	2	1	0
Treatment effect	1	1	1	0	0
Total	13	13	8	2	0

Table 6: Dermatology Life Quality Index Questionnaire

The DLQI score improved from 13 to 0, reflecting a marked improvement in the patient's quality of life.

S.NO.	DOMAIN	30days	60days	90days	120days
01.	Was there an improvement in the main symptom or condition for which the homeopathic medicine was prescribed?	+2	+2	+2	+2
02	Did the clinical improvement occur within a plausible timeframe relative to the medicine intake?	+1	+1	+1	+1
03	Was there a homeopathic aggravation of symptoms?	0	0	0	0
04	Did the effect encompass more than the main symptom or condition (e.g., other unrelated symptoms improved)?	0	0	0	+1
05	Did overall well-being improve?	+2	+2	+2	+2
06	Direction of cure: Did symptoms improve in the opposite order of their development?	0	0	0	+1
07	Did "old symptoms" reappear temporarily during the course of improvement?	0	0	+1	+1
08	Are there alternative causes (other than the medicine) that could explain the improvement?	0	0	0	0
09	Was the health improvement confirmed by objective evidence (clinical exam, investigation)?	0	+2	+2	+2
10	Did repeat dosing, if conducted, create similar improvement?	0	0	+1	+1
	TOTAL	4	7	9	11

Table 7: The MONARCH Criteria

The MONARCH score increased from 4 to 11.

CONCLUSION:

This case study demonstrates that the Homoeopathic constitutional remedy can effectively address both the physical symptoms and the psychological impact of Acne Vulgaris. It shows a positive clinical outcome backed by sequential photographic documentation, providing evidence that Constitutional homoeopathic treatment is a valuable option for acne vulgaris. However, future research should involve a larger sample size to provide definitive proof of the effectiveness Constitutional remedy in treating both the physical and psychological aspects of Acne vulgaris.

FINANCIAL SUPPORT AND SPONSORSHIP: NIL

CONFLICTS OF INTEREST: NIL

ACKNOWLEDGMENT:

I express my heartfelt gratitude to Dr. M. Murugan, Professor and Head, P.G. and Ph.D. Guide, Department of Organon of Medicine & Homoeopathic Philosophy, Sarada Krishna Homoeopathic Medical College, for his support and guidance throughout the completion of this study.

BIBLIOGRAPHY:

1. Healy E, Simpson N. Fortnightly Review Acne vulgaris. *BMJ*. 1994 Mar 26;308(6932):831–3.
2. Vos T, Flaxman AD, Naghavi M, Lozano R, Michaud C, Ezzati M, et al. Years lived with disability (YLDs) for 1160 sequelae of 289 diseases and injuries 1990–2010: a systematic analysis for the Global Burden of Disease Study 2010. *The Lancet* [Internet]. 2012 Dec;380(9859):2163–96. Available from: [https://www.thelancet.com/journals/lancet/article/PIIS0140-6736\(12\)61729-2/fulltext](https://www.thelancet.com/journals/lancet/article/PIIS0140-6736(12)61729-2/fulltext)
3. Stathakis V, Kilkenny M, Marks R. Descriptive epidemiology of acne vulgaris in the community. *The Australasian Journal of Dermatology* [Internet]. 1997 Aug 1;38(3):115–23. Available from: <https://pubmed.ncbi.nlm.nih.gov/9293656/>
4. Bhate K, Williams HC. Epidemiology of acne vulgaris. *British Journal of Dermatology*. 2013 Feb 28;168(3):474–85.
5. Close, S. *The Genius of Homoeopathy: lectures and essays on homoeopathic philosophy*. Indian Books and Periodical Publishers; 2010.
6. Kent, J.T. *Lectures on homoeopathic philosophy*. Indian Books and Periodical Publishers; 2003.
7. Bailey PM. *Homeopathic Psychology: Personality Profiles of the Major Constitutional Remedies*. First Indian edition, 2002.
8. Dr. Dhawale, M.L., *Practice and Principles of Homoeopathy* 3rd edition, 2004.
9. Laishram Bhagat Singh, Sushma Suresh Manhas. Constitutional treatment in homoeopathy: a narrative review. *Sustainability, Agri, Food and Environmental Research*. 2023 Apr 24;13. 7.
10. Hahnemann S. *The Chronic Diseases, Their Peculiar Nature and Their Homoeopathic Cure*. 1904.
11. Hahnemann S, Sarkar BK, Dudgeon RE. *Organon of medicine* (5th and 6th edition). Calcutta: Bhattacharyya; 1976.