



Management of *shophayuktabahyaarshas* (Inflamed thrombosed external hemorrhoids) Through para-Surgical procedure- A case report

SAURABH KUMAR YADAV ^{*1}, MAHESH KUMARES², SHIVANI AC³ SHIVAPRASD⁴

1: PG scholar, Dept. of Shalya Tantra, SDM College of Ayurveda, Hassan.

2: Associate Professor, Dept. of Shalya Tantra, SDM College of Ayurveda, Hassan.

3: Assistance Professor, Dept. of Shalya Tantra, SDM College of Ayurveda, Hassan

4: PG scholar, Dept. of Shalya Tantra, SDM College of Ayurveda, Hassan.

ABSTRACT

A case of 48 years old male, presented with mass over anal verge associated with severe pain and difficulty in sitting since 6 days, during per rectal examination diagnosed as Inflamed Thrombosed external hemorrhoids.

Arshas is a disease of great clinical relevance in the modern era because of improper food habits and sedentary lifestyle, these causes interfere with digestive system which leads to many ailments amongst them ano-rectal diseases constitute a major group. *Arshas* which is compared to haemorrhoids in the contemporary science is the commonest ano-rectal condition seen in the practice of proctology.

External hemorrhoids arise from inferior hemorrhoidal plexus and are covered by squamous epithelium which occur below the pectinate line and may become thrombotic and ulcerate. According to *Acharyas Bahya Arshas* which is hard, bluish red in colour with severe pain which can be co-related to thrombosed external hemorrhoids.

Method: *Jalaukavacharana* which is one among the *Anushastra*/ parasurgical procedure is selected as treatment modality for current case study.

Results: Patient got symptomatic relief by 9th day of *Jalaukavacharana* and Complete cured of Inflamed thrombosed external hemorrhoids within 15 days without surgical intervention using *Jalaukavacharana*.

Conclusion: *Jalaukavacharana* as a *Anushastra* better treatment rather than surgical intervention in *Bahya Arshas* and in patient who are afraid of surgery.

Keywords: *Shopha Yukta Bahya Arshas*, External Thrombosed Hemorrhoids, *Jalaukavacharana*, *Leech therapy*.

INTRODUCTION

According to *Ayurveda* *Arivata* *prāṇinoma* *śakīlākā* *visasantiyatarśāmsita* *mātucyate* *gudamārganirodhahis* defined as (External hemorrhoids) that obstructs anal opening causing severe pain like enemy [1]. *Arshas* (haemorrhoids) is defined as the engorgement of the haemorrhoidal venous plexus, External hemorrhoids arise from inferior hemorrhoidal plexus and are covered by squamous epithelium which occurs below the pectinate line and may become thrombotic and ulcerate, external hemorrhoids which are found at the external anal orifice is of two types one occurs predominantly in the form of dilatation and engorgement of veins beneath the skin and other is manifested as thrombosis of these veins, which is highly painful, associated with difficulty in defecation and sitting [2].

The vitiated *Doshas* (*Vata* (*Vyana Vata*, *Apana Vata*), *Pitta*, *Kapha*) contaminate *Twak*, *Mamsa*, *Medas* and *Raktadhatu* causes *Mamsa ankura* at the anal opening which has symptoms like bluish red hard mass which is extremely painful [3].

According to *Acharya Sushruta Jalauka* is the best among *Anushastra*, *Jalaukavacharana* is one among *Shastrakarma*, according to *Acharya Charaka Jalaukavacharana* is done commonly in *Raja*, *Adhya Rogi*, *Bala*, *Bheeru*, *Vridhdha*, *Stree*, and *Sukumara* [4-7].

In current case study patient was afraid to undergo surgery, so for such patient's parasurgical procedure / *Anushastra* is chosen (i.e. *Jalaukavacharana*), which provides thrombolytic, anti-inflammatory and analgesics effect which helps in reduction of pain and dissolving of thrombus.

Case Report

Complaints of hard mass over anal verge associated with severe pain and difficulty in defecation Since 6 days.

HISTORY OF PRESENT ILLNESS

Patient was apparently healthy 3 days back, suddenly he noticed a mass around anal verge after continuous straining to defecate which gradually increased in size associated with severe pain and difficulty in defecation. So, he approached *Shalya Tantra* ARC OPD

And got admitted in SDM College of Ayurveda and Hospital, Hassan.

History of past illness

No known case of diabetes mellitus, hypertension, thyroid disorder or any other medical disease.

Medical history

He first consulted in Hassan Institute of Medical Science (HIMS) and suggested for surgery, since he was not ready to undergo surgery, patient took some analgesics medication for 2 days from which he didn't get any relief so later he approached SDMCAH Hassan.

Surgical history

No History of surgical intervention

Personal history

Weight – 60kg

Height – 168cm

BMI – 21.3

Appetite – Good

Bowel – Hard stools (1-2 times /day)

Micturition- Regular

Sleep- Disturbed due to pain

Examination of the patient

General examination

General appearance—ill look Nutritional status: poorly nourished

Pallor: Absent

Icterus: Absent

Cyanosis: Absent

Clubbing: Absent

Oedema: Absent

Lymphadenopathy: Absent

Vitals

Bp—120/80mmHg

Temperature—97F

Pulse—74bpm

Respiratory Rate—16cpm

Systemic examination

CNS: Intact, conscious, well oriented to time, place and person

RS: equal air entry to B/L lung field, NBVS present

P/A: Soft, Non-tender and No organomegaly

Per Rectal examination

Inspection—Inflamed Thrombosed External Hemorrhoids at 3, 7 and 11 'O' clock position Digital rectal examination—

Not done due to pain

Proctoscopy—Not done due to pain

INVESTIGATIONS

Hb: 13gm/dl,

TC: 6,400 cells/mm³,

ESR: 02mm/hr,

Blood Urea: 24.9mg/dl,

Serum Creatinine: 0.8mg/dl

HIV & HbsAg: NEGATIVE

LFT—Within normal limit

CXR—PA View—Normal

USG Abdomen & Pelvis—Normal Study

DIAGNOSIS

Shophya Yukta Bhaya Arshas/Inflamed Thrombosed External Haemorrhoids 3, 7 and 11 'O' clock position

TREATMENT GIVEN

Poorvakarma

Prior to *Jalaukavacharana* sitz bath with *Triphalachurna* in lukewarm water for 10 minutes done.

Pradhanakarma

Perianal region is cleaned with normal saline.

Under aseptic precaution activated *Jaluka* was kept over the 3 o'clock 7 o'clock and 11 o'clock inflamed thrombosed external haemorrhoids and waited for 30 minutes or till *Jaluka* leaves its own for 7 days.

Paschatkarma

Post *Jalaukavacharana* there was a triangular wound was created by *Jaluka*, the blood comes out from the post *Jalauka* wound was checked by application of pressure bandaging with use of *Haridra Churna*

Pressure bandaging daily with *Haridrachurna* after *Jalaukavacharana*.

Precaution during Jalaukavacharana

1. Bleeding and clotting time of the patient should be normal
2. Gentle handling of *Jalauka*
3. Cover the *Jalauka* with the wet gauze
4. Remove *Jalauka* if any adverse effects present (e.g. pain, severe itching and allergic reaction etc.)

Oral medication

Tab. *Anulomads* 0-0-2 B/F

Dasamoola Kashaya 100ml TID A/F Tab.

Chandraprabha Vati 2-0-2 A/F

Observation

Pain around the anal region

1 st sitting of <i>Jalaukavacharana</i>	Pain reduced by 30-40%
3 rd sitting of <i>Jalaukavacharana</i>	Pain reduced by 50-60%
5 th sitting of <i>Jalaukavacharana</i>	Pain reduced by 60-65%
7 th sitting of <i>Jalaukavacharana</i>	Pain reduced by 70-80%
9 th sitting of <i>Jalaukavacharana</i>	Pain reduced by 100%

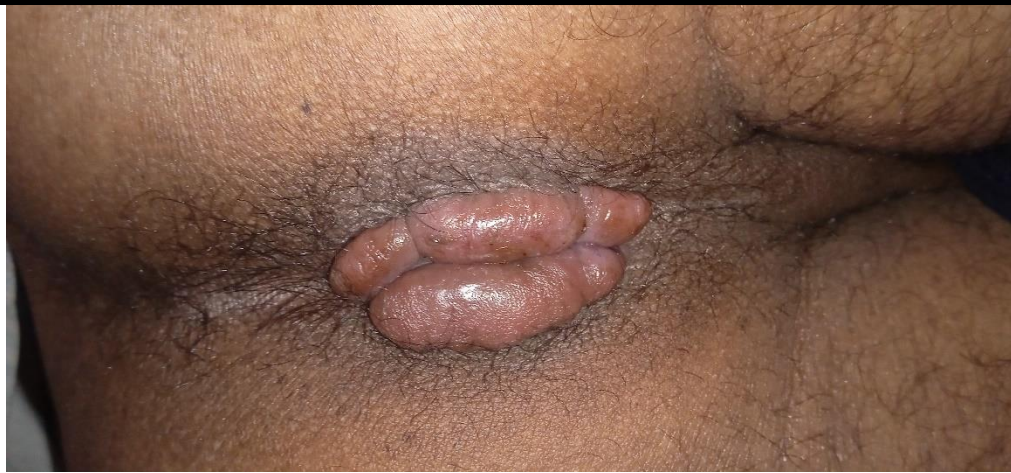Reduction of swelling (Inflamed thrombosed external haemorrhoids)

On 1 st sitting of <i>Jalaukavacharana</i>	Swelling (external haemorrhoids reduced by 10%)
On 3 rd sitting of <i>Jalaukavacharana</i>	Swelling (external haemorrhoids reduced by 30%)
On 5 th sitting of <i>Jalaukavacharana</i>	Swelling (external haemorrhoids reduced by 40%)
On 7 th sitting of <i>Jalaukavacharana</i>	Swelling (external haemorrhoids reduced by 50%)
On 9 th sitting of <i>Jalaukavacharana</i>	Swelling (external haemorrhoids reduced by 70%)
On 15 th day	Complete reduction of Swelling (external haemorrhoids reduced by 100%)

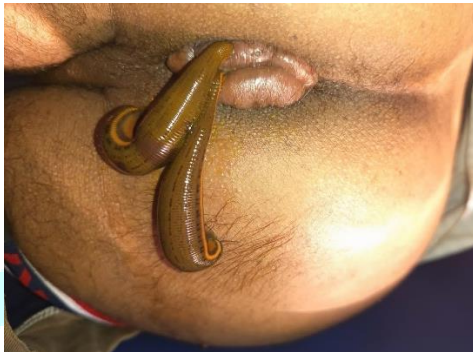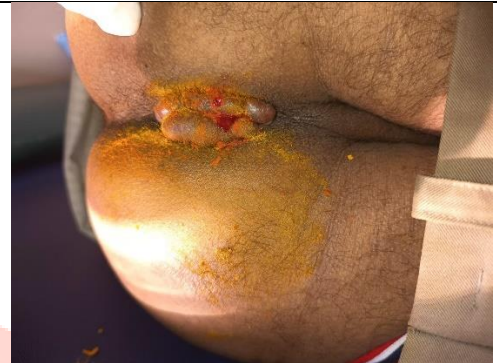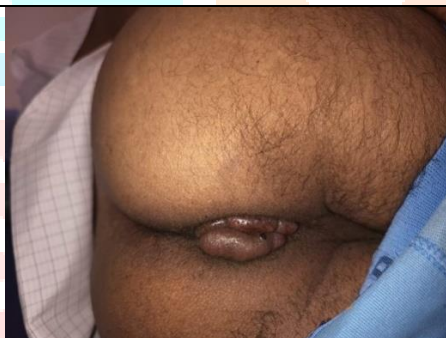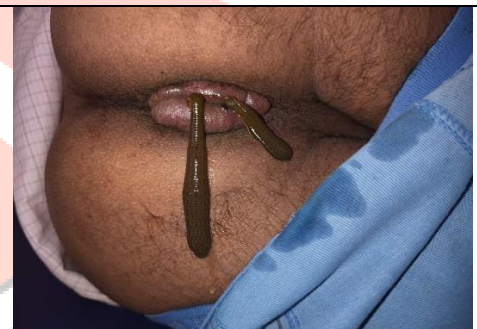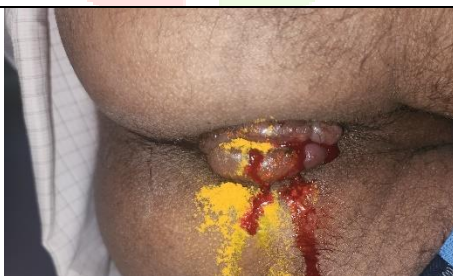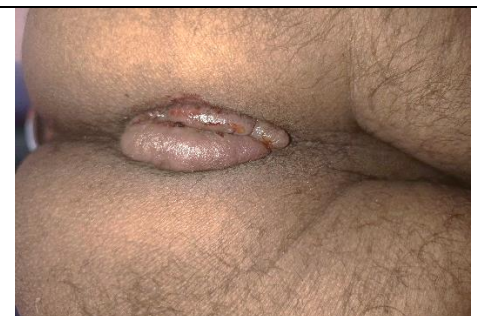RESULTS

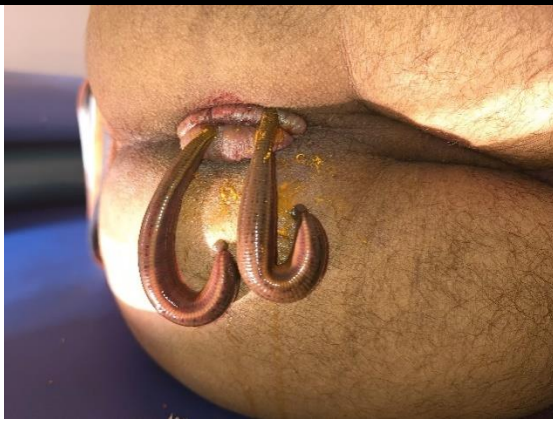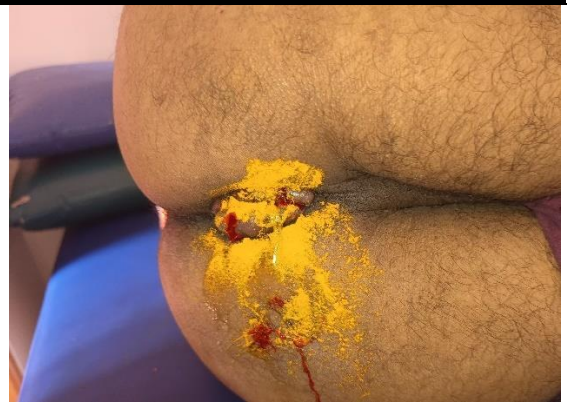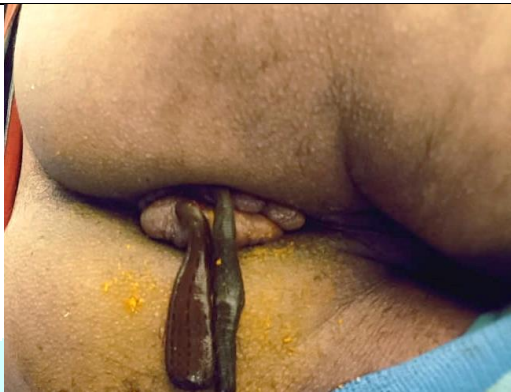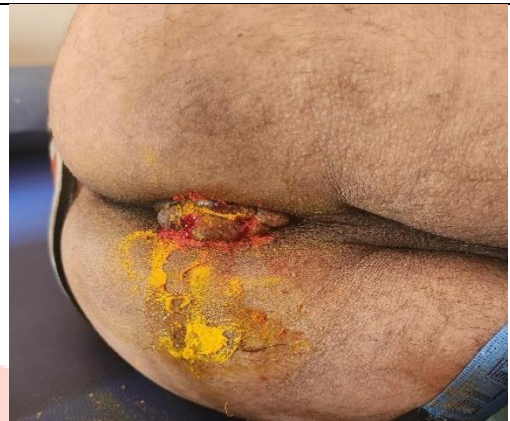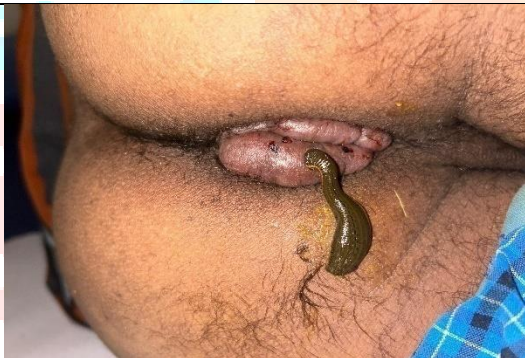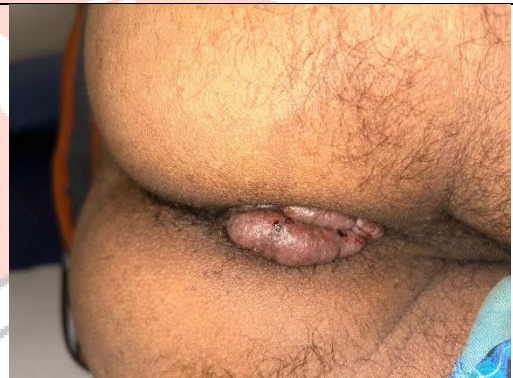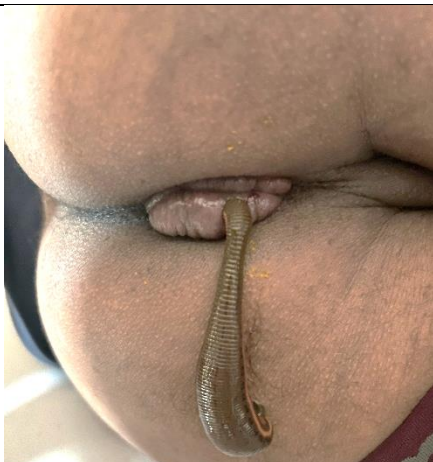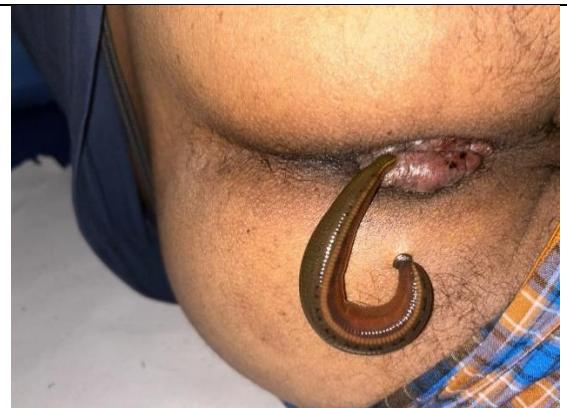Patient got relief from pain by 100% on the day of discharge (5th day).



Discomfort - patient is unable to sit properly and difficulty in defecation on the day of admission, after 1st day sitting of *Jalaukavacharana* patient is able to sit properly and defecate without pain regularly once in a day. Complete resolution of Inflammation on the day of discharge and swelling (external haemorrhoids/*Bahya Arshas*) reduced completely in size after 15 days.



On the day of Admission

1st day During *Jalaukavacharana*After *Jalaukavacharana*2nd day Before *Jalaukavacharana*2nd day During *Jalaukavacharana*2nd day after *Jalaukavacharana*3rd day Before *Jalaukavacharana*

3rd day During *Jalaukavacharana*3rd day During *Jalaukavacharana*4th day During *Jalaukavacharana*4th day During *Jalaukavacharana*5th day During *Jalaukavacharana*5th day During *Jalaukavacharana*7th day During *Jalaukavacharana*8th day During *Jalaukavacharana*

	
9 th day During <i>Jalaukavacharana</i>	After 15 days

DISCUSSION

According to Acharya Sushruta Raktamokshana is considered as *Ardha Chikitsa* of *Shalya Tantra*. *Jalaukavacharana* is one among the *Raktamokshana*, here we selected *Jalaukavacharana* as first line of treatment since *Bhaya Arshas*/inflamed thrombosed external haemorrhoids has occurred due to vitiation of *Vyana Vata*, *Apana Vata*, *Pitta*, *Kapha Dosha* which further contaminate *Twak*, *Mamsa*, *Meda* and *Rakta dhatu* causes *Mamsa ankura*, *Jalaukavacharana* helps in *Rakta and Pitta Vishodana*. So, it helps in reduction of pain and swelling due to blood-letting (*Raktamokshana*) which will allow the patient to sit and lie without discomfort.

Acharya Vagabhata and Sushruta indicated the use of *Jalauka* in *Arsha* since the saliva of leech contains substances such as *bdellin*, *Hirudin*, *Destabilise*, *Hyaluronidase* which act as antioxidant, antibiotic, anticoagulant, and it has thrombolytic, analgesic, anti-inflammatory property which reduces the inflammation, swelling, and dissolves the thrombus by which pain and discomfort are reduced, to support the process of healing. *Anuloma DS* acts as a stimulant laxative and powerful carminative. *Vata Anulomana* and relief from *Vibandha*, *Chandraprabha Vati* pacifies pain, inflammation and does *Shopahara Dashamoola Kashaya* does *Vata Shamaka* and *Sholahara*.

Patient's symptoms are reduced and quality of life is improved after 9th days of *Jalaukavacharana* and completely cured of Inflamed Thrombosed External Haemorrhoids at 3, 7 and 11 o'clock after 15 days.

CONCLUSION

Jalaukavacharana over *Shopa* *Yukta Bahya Arsha* helped in dissolving the thrombus which in turn reduced the pain and discomfort while sitting and defecation. Thus, it can be concluded that use of *Jalaukavacharana* over *Shopa Yukta Bahya Arsha* (Inflamed thrombosed external haemorrhoids) is found to be effective para-surgical procedure and without any surgical intervention symptoms can be reversed and quality of life can be improved or regained.

REFERENCES

- [1] Bhatt S. SRB Manual of Surgery. 5th ed. New Delhi: Jaypee the health science publisher; 2017. p.977-978
- [2] Vd. Ambikadatta Shashtri-Sushrut Samhita Purvardh-
Su. Su. 33/4 Pg. No. 126 Chukhambha Sanskrit Samsthan Varanasi Publisher; 2007
- [3] Vd. Ambikadatta Shashtri-Sushrut Samhita Purvardh-
Su. Sha. 6/9 Pg. No. 52, Chukhambha Sanskrit Samsthan Varanasi Publisher; 2007.
- [4] Vd. Ambikadatta Shashtri-Sushrut Samhita Purvardh-
Su. Chi. 6/7 Pg. No. 37, Chukhambha Sanskrit Samsthan Varanasi Publisher; 2007
- [5] Vagbhatta Astanga Hridayam Vol. 2-
K. R. Srikanth Murthy 7th Arsho Nidana Adhyaya Varanasi: Chaukhamba Publication; 2021.
- [6] Caraka Samhita: Text with
English Translation & Critical Exposition Based on Cakrapani Datta's Ayurveda Dipika (4th Volume) 14th chapter
Arsho chikitsa – 1 January 2009.
- [7] Astanga Sangraha: Vol. 2 – K. R. Srikanth Murthy 7th Arsho
Nidana Adhyaya Varanasi: Chaukhamba Publication; 1999.

