



# A Literary Review Of Shalyaja Nadi Vrana And Pilonidal Sinus

<sup>1</sup>Dr. Rohan Dilip Pokale, <sup>2</sup> Dr. Shaista Raj Jamadar, <sup>3</sup>Dr. Gudasi Duradundi

<sup>1</sup> Second Year Post Graduate Scholar, Dept. of Shalyatantra, Dr. N. A. Magdum Ayurvedic College, Hospital, Ankali, Belgaum, Karnataka

<sup>2</sup> Associate Professor, Dept. of Shalyatantra, Dr. N. A. Magdum Ayurvedic College, Hospital, Ankali, Belgaum, Karnataka

<sup>3</sup> Professor, HOD, Dept. of Shalyatantra, Dr. N. A. Magdum Ayurvedic College, Hospital, Ankali, Belgaum, Karnataka

## Abstract

Pilonidal sinus is a chronic inflammatory condition predominantly affecting the sacrococcygeal region, characterized by a tract or cavity containing hair and debris. It is most common in young adult males and presents a therapeutic challenge due to its recurrent nature. In Ayurvedic medicine, this condition is correlated with *Shalyajanya Nadi Vrana* a subtype of sinus wound caused by a foreign body (*Shalya*), typically hair. This review synthesizes classical Ayurvedic concepts with contemporary surgical approaches, highlighting the pathogenesis, clinical features, and management strategies. Special emphasis is placed on Ayurvedic para-surgical techniques such as *Kshara Karma* and *Kshara Sutra*, which have demonstrated efficacy in reducing recurrence rates and promoting healing.

Keyword: *Shalyaja Nadi Vrana*, Pilonidal Sinus, *Kshara Sutra*, *Ayurveda*

## Introduction

Pilonidal sinus, derived from Latin meaning "nest of hair," is a benign but persistent condition that affects the intergluteal cleft near the sacrococcygeal region. First described by Herbert Mayo in 1833 and later termed "jeep disease" during World War II due to its prevalence among military drivers, it is now recognized as an acquired condition resulting from hair penetration into the skin.

In Ayurveda, this condition is identified as *Nadi Vrana*, particularly the *Shalyajanya* type. The term "*Nadi*" refers to a tract, and "*Vrana*" to an ulcer. Thus, *Nadi Vrana* is defined as an ulcer with a tract, often caused by a foreign body such as hair (*Bala Shalya*).<sup>1</sup>

## Etiopathogenesis

## Modern Perspective

Pilonidal sinus is believed to result from hair insertion into the skin, leading to a foreign body reaction. The most widely accepted theory is that of acquired etiology due to hair implantation. Risk factors include:

- Prolonged sitting and friction
- Obesity and excessive sweating
- Poor hygiene and hairy body
- Active pilosebaceous glands in young adults

Histological studies confirm the presence of granulation tissue and foreign body giant cells surrounding hair shafts, supporting the theory of hair-induced inflammation.<sup>2</sup>

## Ayurvedic Perspective

According to *Sushruta Samhita*, *Nadi Vrana* arises when an immature abscess (*Apakwa Vrana Shopha*) is improperly drained, or due to unhealthy diet and lifestyle (*Ahita Ahara-Vihara*). The presence of a foreign body (*Shalya*) initiates tract formation, which eventually bursts through the skin, discharging frothy pus (*Phenayukta Puya*) mixed with blood.<sup>3</sup>

The discharge is continuous and painful, exacerbated by movement. This form is classified as *Shalyajanya Nadi Vrana* and is considered *Kricchrasadhya* (difficult to cure).

Classification of *Nadi Vrana*

According to *Sushruta* <sup>4</sup>

Type	Predominant Dosha
<i>Vataj</i>	<i>Vata</i>
<i>Pittaj</i>	<i>Pitta</i>
<i>Kaphaj</i>	<i>Kapha</i>
<i>Vata-Pittaj</i>	<i>Vata + Pitta</i>
<i>Pitta-Kaphaj</i>	<i>Pitta + Kapha</i>
<i>Vata- Kaphaj</i>	<i>Vata + Kapha</i>
<i>Sannipataj</i>	<i>Vata + pitta + Kapha</i>
<i>Shalyajanya</i>	<i>Agantuja</i> (Foreign Body)

According to Vagbhata <sup>5</sup>

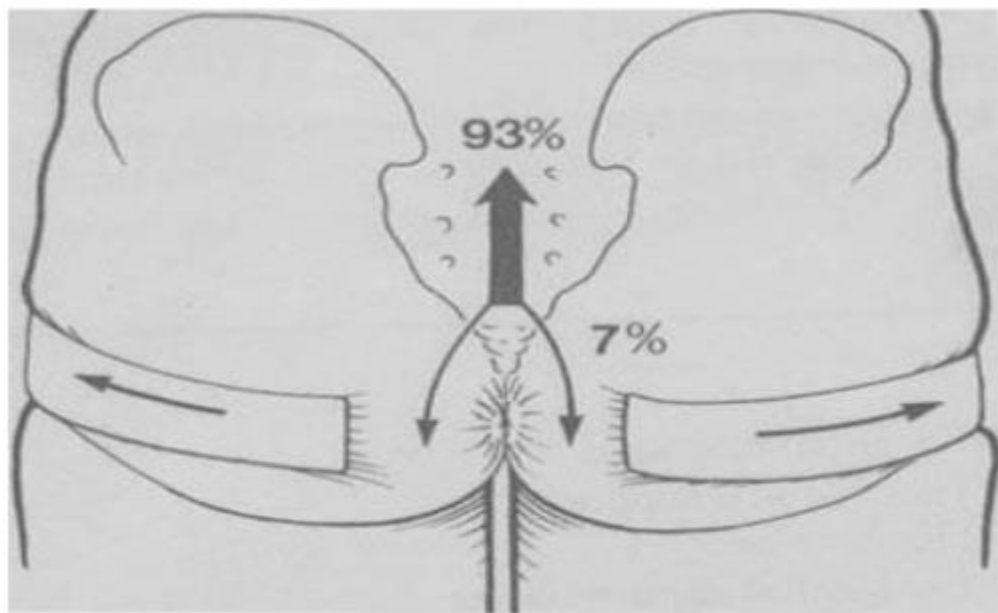
- *Vataja*
- *Pittaja*
- *Kaphaja*
- *Sannipataja*
- *Shalyajanya*

Clinical Features<sup>6</sup>

- Midline pits located 4–8 cm from the anus
- Serosanguinous or purulent discharge
- Tuft of hair visible at the sinus opening
- Throbbing or persistent pain
- Tender swelling near the coccyx

## Direction of sinus tract spread:

- 93% cranially
- 7% caudally toward the anus



## Management Strategies

## Modern Surgical Approaches

1. **Incision and Drainage (I&D):** Effective for acute abscesses; 50% may not recur.

2. **Excision Techniques:**

- Simple excision
- Excision with marsupialization
- Excision with primary closure

**Advanced Procedures:**

- Karydakis flap
- Bascom's procedure
- Limberg flap
- Z-plasty, V-Y plasty

3. **Adjunctive Measures:**

- Hair removal

- Fibrin glue application

Ayurvedic Management <sup>7</sup>

*Samanya Chikitsa* (General Treatment)

- ***Pratisarneeeya Kshara***: Caustic alkali used for all types of *NadiVrana* <sup>8</sup>
- ***Bhedana Karma***: Incision for tract opening <sup>9</sup>
- ***Chedana Karma***: Excision of foreign body lodged in tissue <sup>10</sup>
- ***Shodhana and Ropana***: Cleansing and healing using *Madhu* (honey), *Ghrita* (ghee), and *Tila Kalka* (sesame paste)

*Patana Karma* (Surgical Technique) <sup>11</sup>

- Probing the tract to determine direction
- Opening the entire tract
- Cleansing and dressing until complete healing

Para-Surgical Techniques

### 1. ***Kshara Karma***:

It is a procedure where in *Bhedana* (incision), *Chedana* (excision) and *Lekhana* (scrapping) are performed by employing some specially formulated *Yogas* called *Kshara* (caustic alkali). Patient is made to lie down in prone position. Then probing is done to see the length of the tract. With the help of scalpel an elliptical incision is made around the pilonidal sinus. The whole sinus tract will be excised deep upto the presacral fascia. After the above *Chedana Karma*, *Pratisarneeeya Kshara* will be applied. After application of the *Kshara* wait for 100 *Matra Kala* (1 minute), then wash with *Nimbu Swarasa* (lime juice) to operative wound. During post-operative period daily dressing will be done till wound gets completely healed.

### 2. ***Kshara Sutra***: <sup>12</sup>

It is a special technique of excision without the use of knife by means of mechanical pressure and chemical action. *Sushruta* has indicated the use of *Ksharasutra* in *Nadi Vrana* where the patients are emaciated, timid and located at the *Marma Sthanans* (vital parts). Here probing is done through the opening and tract traced till its blind end and an opening is made at that site. Probe removed through created opening after feeding of *Kshara Sutra* and then ligated properly, weekly *KsharaSutra* changing will be done till the tract cut off.

Preventive Measures

- Regular hair removal and hygiene
- Weight management
- Correction of diet and lifestyle

## Discussion

Ayurvedic interventions such as *Kshara Karma* and *Kshara Sutra* offer minimally invasive, outpatient-friendly alternatives to conventional surgery. These techniques combine mechanical and chemical actions, fulfilling the principles of *Chedana*, *Bhedana*, and *Lekhana* from *Ashtavidha Sastra Karma*.<sup>13</sup> Studies have shown that these methods significantly reduce recurrence rates and promote effective healing.

## Conclusion

Pilonidal sinus remains a therapeutic challenge due to its recurrent nature. While modern surgical techniques offer various options, Ayurvedic approaches—particularly *Kshara Sutra* and *Kshara* application—demonstrate promising outcomes with minimal invasiveness and reduced recurrence. Integrating these traditional methods into contemporary practice can enhance patient care and long-term results.

## References

1. Dr. S Das, A Concise Textbook of Surgery, 3rd ed., Calcutta, 2001, p.1075.
2. Vagbhata, Ashtanga Hrdayam, volume 111, edited by K.R. Srikantha Murthy, Chowkhamba Krishnadas Academy, Varanasi, 2006, utara sthana, chapter 29, Granthi Arbuda Slipada Apaci Nadi Vijnaniya, p279.
3. Sriram Bhat, SRB's Manual of Surgery, 5th ed., Jaypee Brothers, New Delhi, 2015, p.967.
4. Susrutha, Susrutha samhita, vol.11, edited by Kaviraj Kunjalal Bhishagratna, 2nd ed. Varanasi: Chowkhambha Sanskrit Series Office, 2002. Nidanasthana, chapter10, Visarpa Nadi Sthana Roga Nidanam, p80
5. Vagbhata, Ashtanga Hrdayam, volume 111, edited by K.R. Srikantha Murthy, Chowkhamba Krishnadas Academy, Varanasi, 2006, utara sthana, chapter 29, Granthi Arbuda Slipada Apaci Nadi Vijnaniya, p279.
6. Bailey and Love's Short practice of surgery, edited by R.C.G. Russell, Norman. S. Williams, Christopher. J.K, Bulstrode, 24th ed. Great Britain, Hodder Education, 2004, Chapter 72, The Anus and Anal Canal, p1249.
7. Susrutha, Susrutha Samhita, vol.1, edited by Kaviraj Kunjalal Bhishagratna, 2nd ed. Varanasi: Chowkhambha Sanskrit Series Office, 2002, sutrasthana, chapter 25, Ashtavidhasastrakarmaadhyaya, p223.
8. Susrutha, Susrutha Samhita, vol.1, edited by Kaviraj Kunjalal Bhishagratna, 2nd ed. Varanasi: Chowkhambha Sanskrit Series Office, 2002, sutrasthana, chapter 25, Ashtavidhasastrakarmaadhyaya, p223.
9. Susrutha, Susrutha Samhita, vol.1, edited by Kaviraj Kunjalal Bhishagratna, 2nd ed. Varanasi: Chowkhambha Sanskrit Series Office, 2002, sutrasthana, chapter 25, Ashtavidhasastrakarmaadhyaya, p223.
10. Susrutha, Susrutha Samhita, vol.1, edited by Kaviraj Kunjalal Bhishagratna, 2nd ed. Varanasi: Chowkhambha Sanskrit Series Office, 2002, sutrasthana, chapter11, ksharapakavidhi adhyaya, p76
11. Susrutha, Susrutha Samhita, vol.1, edited by Kaviraj Kunjalal Bhishagratna, 2nd ed. Varanasi: Chowkhambha Sanskrit Series Office, 2002, sutrasthana, chapter 25, Ashtavidhasastrakarmaadhyaya, p223.

12. Susruta, Dalhana, Susruta Samhita Nibandha Sangraha commentary, edited by Vaidya Jadavji Trikamji, Varanasi: chowkhamba Krishnadas Academy, 2008, chikitsasthana, chapter 17, visarpanadisthana rogachikitsa adhyaya, p468.
13. Susruta, Susruta Samhita, vol.1, edited by Kaviraj Kunjalal Bhashagratna, 2nd ed. Varanasi: Chowkhambha Sanskrit Series Office, 2002, sutrasthana, chapter 25, Ashtavidhasastrakarmaadhyaya, p223.

